

Porcine circovirus as a possible cause of postweaning wasting in pigs in Switzerland

S. Staebler¹, E. Buergi², B. Litzenberger³, K. McCullough⁴, I. McNair⁵, F. McNeilly⁵, A. Pospischil¹, T. Sydler¹

¹ Institute of Veterinary Pathology, ² Department of Farm Animals, Section of Swine Medicine and ³ Institute of Veterinary Bacteriology, University of Zurich, Switzerland, ⁴ Institute of Virology and Immunoprophylaxis, Mithras, Switzerland, ⁵ Virology Department, Veterinary Sciences Division, Department of Agriculture and Rural Development, Stoney Road, Belfast BT4 3SD, Northern Ireland, UK

Summary

Postweaning wasting is a major worldwide problem in pig production, particularly with respect to the disease termed postweaning multisystemic wasting syndrome (PMWS). In addition to wasting, PMWS symptoms include respiratory distress, diarrhoea, pallor and occasional cases of jaundice. The causative agent is porcine circovirus type 2 (PCV-2). The objective of the present study was to determine the significance of PMWS and similar conditions in Switzerland. A total of 72 weaned piglets from 26 farms showing wasting were examined for the presence of PCV-2 by immunohistochemical and histological analysis and 57 piglets from 21 farms were examined serologically. Possible causes for wasting other than PCV-2 were investigated by macroscopic, histological and bacteriological methods. PCV-2 antigen was identified immunohistochemically in the lymphatic organs in 11 of these 72 piglets. However, only 4 animals showed histological changes typical of PMWS. PCV-2 antibodies were found in 70% of the piglets. Piglets with wasting syndrome not associated with PCV-2 infection suffered from conditions including porcine proliferative enteropathy, gastric ulcers, polyserositis and polyarthritis. The most frequent condition was chronic enteritis not associated to circovirus infection. The results from the serological analyses indicate a wide distribution of PCV-2 in the Swiss pig population. However, confirmed cases of PMWS were rare in the investigated piglets.

Porzines Circovirus als mögliche Ursache von Kümern nach dem Absetzen von Ferkeln in der Schweiz

In der Schweineproduktion ist das Auftreten von Kümern nach dem Absetzen ein weltweit vorkommendes Problem. «Postweaning multisystemic wasting syndrome» (PMWS) ist ein neuer Krankheitsbegriff, der jene Fälle von Kümern nach dem Absetzen beinhaltet, bei denen Tiere nachweislich an einer Infektion durch Porzines Circovirus Typ 2 (PCV-2) erkrankt sind. Neben Kümern treten klinisch auch respiratorische Symptome, Durchfall, Blässe und gelegentlich Ikterus auf. Ziel dieser Arbeit war es, die Bedeutung von PMWS und anderer Erkrankungen, welche mit Kümern einhergehen, in der Schweiz zu untersuchen. Insgesamt wurden 72 abgesetzte und kümmernde Ferkel aus 26 Betrieben mittels Immunhistochemie und histologischen Untersuchungsmethoden auf das Vorhandensein von PCV-2 untersucht. 57 Ferkel aus 21 Betrieben wurden zusätzlich serologisch auf Antikörper gegen PCV-2 getestet. Jedes Tier wurde nach der Euthanasie eingehend makroskopisch und histologisch sowie der Magen-Darmtrakt und die parenchymatösen Organe auch bakteriologisch untersucht. In den lymphatischen Organen von 11 der 72 Ferkel konnte PCV-2 immunhistochemisch nachgewiesen werden. Von diesen 11 positiven Tieren wiesen aber nur 4 die für PMWS typischen histologischen Veränderungen auf. PCV-2 Antikörper konnten hingegen in 70% der Ferkel aufgefunden werden. Andere Krankheiten, die ohne nachweisliche Circovirusinfektion bei kümmernden Ferkeln gefunden wurden, waren unter anderem die Porzine Proliferative Enteropathie, Magengeschwüre, Polyserositiden und Polyarthritiden. Histomorphologisch am häufigsten wurden bei den nicht PMWS-Fällen Veränderungen am Darmtrakt in Form chronischer Enteritiden gefunden. Die Resultate der serologischen Untersuchung weisen auf eine weite Verbreitung von PCV-2 in der

Key words: wasting, PMWS, PCV-2, diarrhoea, pig

schweizerischen Schweinepopulation hin, Erkrankungen durch PCV-2 konnten hingegen in den untersuchten Tieren nur selten nachgewiesen werden.

Schlüsselwörter: Kümmern, PMWS, PCV-2, Durchfall, Schwein

Introduction

Postweaning multisystemic wasting syndrome (PMWS) is a major worldwide disease of considerable economic concern, contributing to wasting in weaned pigs (Allan et al., 2003). Wasting associated with this disease is often accompanied by respiratory distress, diarrhoea, pallor and occasional cases of jaundice (Harding et al., 1998). Typical macroscopic findings are enlarged lymph nodes and non-collapsed lungs with interstitial pneumonia (Rosell et al., 1999). PMWS was first observed in 1991 in Canada. It was first described as a specific porcine disease in 1996 (Clark, 1996; Harding, 1996) and subsequently identified in many countries of Europe, North America and Asia (Allan and Ellis, 2000). The causative agent has been identified as porcine circovirus type 2 (PCV-2) (Ellis et al., 1998; Allan et al., 1998; Choi and Chae, 1999). Sorden (2000) defined that three conditions must be satisfied for a diagnosis of PMWS: the occurrence of typical clinical signs, characteristic histological changes in the lymphatic organs and the detection of PCV-2 in the lesions. Histological changes typical of PMWS comprise various degrees of lymphocyte depletion, with infiltration of large histiocytes and multinucleated giant cells in lymphatic organs. Intracytoplasmic inclusion bodies have been detected sporadically in histiocytes (Rosell et al., 1999).

Serological studies have shown that antibodies against PCV-2 are widespread in the pig population. Seroconversion against PCV-2 normally occurs 3 to 4 weeks after weaning and antibodies against PCV-2 can be found in high-status specific pathogen-free (SPF) herds, in large livestock populations and in small herds (Allan and Ellis, 2000). Diseases other than PMWS that can lead to increased wasting after weaning, include porcine proliferative enteropathy (PPE) (McOrist and Gebhart, 1999), dysentery, porcine intestinal spirochetosis (PIS) (Hampson and Trott, 1999; Harris et al., 1999), as well as polyserositis and polyarthritis. Porcine proliferative enteropathy has been observed in Switzerland over the last few years in weaned pigs, but to date there have been no reports of dysentery and porcine intestinal spirocheto-

sis. Switzerland's domestic pig population is free of Aujeszky's disease, classical swine fever (Swiss Federal Veterinary Office – <http://www.bvet.admin.ch>) and porcine reproductive and respiratory syndrome virus (PRRSV) (Thür et al., 2003).

In view of the worldwide distribution of PMWS, it is likely that this disease could be contributing to the postweaning wasting observed in Switzerland. The first description of two clinical cases of PMWS (Borel et al., 2001) and the retrospective detection of PCV-2 antigen in stored tissue samples from Swiss pigs over two decades (Staebler et al., in press) confirm this suspicion. Nevertheless, a clue to the proportion of PMWS in wasting problems of weaned piglets in Switzerland is still missing.

Animals, Materials and Methods

Animals and farms

A total of 72 pigs, 4 to 16 weeks old, from 26 farms with previous therapy resistant wasting problems after weaning were investigated. The farms were located in eastern Switzerland and only these with over 10% wasting weaners were included in this study. Field veterinarians selected 2 or 3 piglets from each farm based on clinical signs of loss of body condition after weaning as the main problem, with the additional symptoms of diarrhoea, skin pallor, jaundice and/or respiratory disorders. The pigs were euthanised and bled after clinical examination at the Department of Farm Animals. All farms were regularly visited by veterinarians of the Swiss Swine Health Organisation (Verband Schweinegesundheitsdienst Schweiz) and were free of mange, lice, rhinitis atrophicans and *Salmonella choleraesuis*. The majority of the examined farms were also free of enzootic pneumonia (EP) and *Actinobacillus pleuropneumoniae* (APP). The average size of the investigated farms was 64 breeding sows (14–150 sows). The piglet's breeds were Swiss Large White or Swiss Landrace with a few crossbreds with Hampshire or Duroc.

Necropsy and histopathology

Samples of mesenteric and inguinal lymph nodes, spleen, tonsils, duodenum, jejunum, ileum, caecum, colon, lung and occasionally brain were collected and fixed in 10% buffered formalin at postmortem examination. After fixation and embedding in paraffin, sections (2–3 µm) were cut and stained with haematoxylin and eosin (HE) by standard methods. Sections from duodenum, jejunum, ileum, colon and caecum were additionally stained by modified Warthin–Starry (W&S) silver impregnation (Arrington, 1994).

Immunohistochemical detection of PCV-2

Sections of lymph nodes, spleen, tonsils and ileum were examined immunohistochemically for PCV-2 using the ORF2-specific monoclonal antibody F217 cell supernatant (McNeilly et al., 2001). The slides were incubated with pronase for 60 minutes and rinsed with Tris-buffered saline containing Tween-20 (TBS/T20) (Wash Buffer 10x, S3006, DakoCytomation). The monoclonal antibody was diluted 1:2 in dilution buffer (S2022, DakoCytomation) and reacted with the sections for 60 minutes. After neutralising the endogenous peroxidase activity (Peroxidase-Blocking Solution, S2023, DakoCytomation), the slides were rinsed with TBS/T20 and incubated with the secondary dextran-bound peroxidase-conjugated goat anti-mouse/rabbit antibody (Envision-Kit Mouse/Rabbit K5007, DakoCytomation) for 30 minutes. The detection step was performed with amino-ethyl-carbazol (AEC/H₂O₂ Substrate Solution, K5003, DakoCytomation) for 10 minutes. Finally, the sections were counterstained with haematoxylin. The immunohistochemical reactions were carried out in the DakoCytomation Autostainer at room temperature. PCV-2 positive tissues from the cases described by Borel (2001), were used as positive controls.

Serology

57 sera from 21 farms were tested for antibodies against PCV-2 by indirect peroxidase monolayer assay (IPMA). Plates were prepared using PCV-free PK15 cells. Confluent flasks were dispersed using trypsin/versene solution and resuspended in Hanks balanced salt solution (HBSS, 21090-022, Gibco) containing 1% foetal bovine serum. PCV-2 virus was added to this cell suspension and incubated with continuous mixing on a blood tube rotator for 2–4 hours at 37°C. Following centrifugation at 250 X g for 5 min, the cells were resuspended in 10 ml of a 300 mM D-glucosamine solution prepared in HBSS and incubated at 37°C for 10 minutes with continuous mixing. After a further centrifugation at 250 X g for 5 minutes, the cells were resuspended in growth

medium (Modified Eagle Medium, (61100-087, Gibco) with Earle's salts supplemented with 10% foetal calf serum and 100 µg/ml gentamicin) and seeded in microtitre plates to give a monolayer within 48–72 hours. After removal of the supernatant the monolayer was washed with phosphate buffered saline (PBS). The plates were then air dried, sealed and stored at least overnight at –20°C. Prior to use, the plates were thawed and 100 µl of a 4% paraformaldehyde solution added to each well. The paraformaldehyde was removed and the plates washed 3 times with phosphate buffered saline containing 0.05% Tween 80 and 10% horse serum (PBS-TH). 100 µl of methanol containing 0.3% hydrogen peroxide was added to each well for 5 minutes at room temperature and washed as before. Serum dilutions were prepared in PBS-TH and 50 µl of each dilution added to each well. After incubation at 37°C for 1 hour the plates were washed 3 times with PBS-TH. 50 µl of rabbit anti-swine peroxidase conjugate (Rabbit anti swine immunoglobulins HRP P0164, DakoCytomation) diluted in PBS-TH were added and plates were incubated for an hour at 37°C. After washing 3 times as before, 50 µl of AEC were added and plates kept for 15 minutes at room temperature in the dark. Washing 4 times with distilled or deionised water stopped the reaction. The cells were examined for the presence of PCV-2 specific red staining, predominantly in the cell nucleus, by bright-field microscopy. The starting dilution employed in this assay was 1:50, because known negative sera diluted less than 1:50 can give false positive results.

Bacteriological examination

Sections from the duodenum, jejunum, ileum and colon were examined for the following pathogens:

- Enterotoxigenic and -toxic *Escherichia (E.) coli*: culture of intestinal content on sheep blood agar (aerobic atmosphere, 37°C, 24h) and subsequent serotyping of haemolytic *E. coli* colonies with antisera against the serogroups O139, O141 and against fimbrial antigen F4 (K88).
- *Salmonella spp.*: Culture with and without pre-enrichment in tetrathionate broth on selective media (Brilliant Green Agar, Becton Dickinson; Gassner agar, Oxoid) and subsequent serotyping of typical colonies with Salmonella omnivalent antiserum (Omnivalentes Testreagens Anti-Salmonella A-67, Sifin).
- *Campylobacter spp.*: Culture on selective medium (Butzler, Oxoid) in microaerophilic atmosphere at 42°C for 48 hours.
- *Yersinia spp.*: Culture on selective medium (CIN, Oxoid) at 30°C for 48 hours and subsequent biochemical typing of typical colonies by standard methods.

- *Lawsonia (L.) intracellularis*: microscopic examination of stamp stained smears from the mucosa of the ileum and colon.
- *Brachyspira (B.) spp.*: culture of faecal swabs and of mucosal samples of the colon on blood agar supplemented with spectinomycin (250 µg/ml; anaerobic atmosphere, 42° C, 6d) and subsequent biochemical typing of typical colonies by standard methods.

Cultures of liver, kidney and spleen on blood- and Gassner agar were performed systematically (aerobic atmosphere 37° C, 48h). Other organs were only cultivated when they showed macroscopic changes.

Results

Macroscopic findings

All 72 piglets were severely emaciated, and their growth was significantly retarded. A total of 56 piglets had mushy to liquid diarrhoea and 17 of these had obvious anaemia with pinkish to whitish mucosae (Tab. 1). Enlargement of the mesenteric and/or inguinal lymph nodes was observed in 16 of the 72 piglets. Ten animals showed only a slight and 6 animals a distinct enlargement of the lymph nodes. Focal to multifocal consolidations in the lungs were found in 13 piglets. In 8 cases the lesion were categorized as bronchopneumonia. The other 5 cases showed foci of lung necrosis with pleura involvement: twice in the caudal lobe, once in the cranio-ventral region, and 2 animals exhibited a multifocal distribution over all lung lobes. These lesions were consistent with either subacute fibrinous or thromboembolic pneumonia re-

spectively. Pleural changes, diffuse fibrous pleuritis, were found in 2 piglets, and diffuse fibrinous pleuritis in 1 animal. Eight piglets showed ulcerations in the pars proventricularis of the stomach, with 2 of them with severely contracted mucosa in the pars proventricularis. Multiple malformations, brachygnathia inferior, scoliosis and kyphosis, were found in 1 piglet. Further single pathological changes are listed in Table 1.

Histological, immunohistochemical and bacteriological findings

Lymphatic organs

A total of 4 pigs satisfied the conditions for the diagnosis of PMWS defined by Sordon (2000). Three piglets showed depletion of the lymphatic organs with infiltration of histiocytes. In 2 of them, multinucleated giant cells were also found in the lymph nodes and Peyer's patches of the ileum as well as in the tonsils of 1 animal. One animal with depletion of the lymphatic organs and giant cell formations showed also a suppurative lymphadenitis in the mesenteric lymph nodes and intracytoplasmic inclusion bodies characteristic of PCV-2 in the lymph nodes, ileum and tonsils. A fourth animal merely exhibited giant cells in the Peyer's patches of the ileum without obvious lymphatic depletion. In all 4 piglets, PCV-2 antigen could be found in the lymphatic organs, being confined to the described lesions. Virus antigen was seen particularly in the cytoplasm of histiocytes in and around the lymphoid follicles or in the sinuses of the lymphatic organs (Fig. 1). The multinucleated giant cells as well as the in-

Table 1: Macroscopic lesions, occurrence of PCV-2 and histological lesions typical for PMWS in 72 pigs

Macroscopic findings	n	%	Detection of PCV-2 without histological PMWS lesions*	Detection of PCV-2 and histological PMWS lesions*
Emaciated	72	100	7	4
Diarrhoea	56	78	6	3
Anemia	17	24		
Consolidations in the lungs	13	18	1	2
Necrotizing ileitis	10	14	2	
Obvious enlargement of lymph nodes	6	8	2	3
Erosive stomach ulcers	6	8	1	1
Diffuse pleuritis	3	4	1	1
Polyserositis with polyarthrit	3	4		
Ulcers with cardiasthenosis	2	3		
Malformations	1	1		1
Polyarthrit with osteomyelitis	1	1		
Polyarthrit	1	1		
Polyserositis	1	1	1	
Arthrit	1	1	1	
Arthrit with osteomyelitis	1	1		
Abscesses and pus in the abdominal cavity	1	1		

* Histological lesions of PMWS consist of lymphocyte depletion with infiltration of large histiocytes and multinucleated giant cells in lymphatic organs

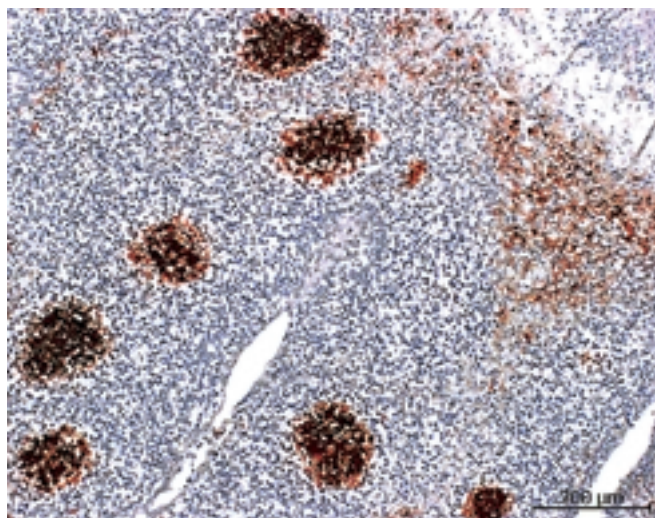


Figure 1: Lymph node. Presence of PCV-2 antigen in histiocytes in the lymphfollicles and sinuses. Immunohistochemistry.

tracytoplasmic inclusion bodies contained PCV-2 antigen. A very high virus load was observed only in the piglet with inclusion bodies. The remaining 3 piglets exhibited a moderate virus load in the lymphatic organs. In 7 other piglets, PCV-2 antigen could be detected in the lymphatic organs without the lesions necessary for a diagnosis of PMWS.

Intestine

Histological lesions were found in the gut of 50 piglets out of 69 histologically and bacteriologically investigated animals (Tab. 2). In 10 piglets the lesions consisted of crypt hyperplasia and hypertrophy in the ileum with superficial necrosis. *Lawsonia intracellularis*-like bacteria could be found in 9 of the 10 animals with necrotizing ileitis, both by silver-staining (W&S) and by the microscopic examination in the stamp stained smears. Another 40 piglets showed mild to moderate chronic inflammation either only in the small intestine (13 animals), or only in the caecum and colon (16 animals) or in the small and large intestine (11 animals). 19 animals showed no histomorphological changes in the gut (Tab. 2). Most colonic and caecal changes consisted of slight to moderate lympho-plasmacellular infiltrates in the lamina propria. In 3 piglets with colitis the lesions were superficial and necrotizing. In 1 of

these piglets silver-stainable bacteria were end-on attached to the surface epithelium typical for *Brachyspira pilosicoli* (Taylor et al., 1980), and *Brachyspira pilosicoli* was identified bacteriologically. In another piglet from the same farm *Brachyspira pilosicoli* was isolated but no adherence was visible. Additional bacteria were isolated from most animals, but no coherence between the histological lesions and the bacteriological findings was recognisable. Six piglets with histological abnormalities in the intestine had no detectable bacterial pathogens.

Lung

Five of the 8 macroscopically diagnosed cases of bronchopneumonia were confirmed histologically as bronchopneumonias, but only 1 of the 5 showed lymphatic infiltrates and epithelial hyperplasia indicative of EP. Giemsa staining of bronchial mucous of this lung detected *Mycoplasma spp.*. One other animal of the 8 macroscopically diagnosed cases of bronchopneumonia showed multifocal necrotizing bronchopneumonia most probably due to the isolated *Bordetella bronchiseptica*. Two pigs of the 8 showed histologically an interstitial pneumonia with mild thickening of the alveolar walls, mainly due to the infiltration of macrophages. Another 4 animals with macroscopically unsuspecting lungs showed histologically the same type of interstitial pneumonia. In total were 6 animals with interstitial pneumonia whereof 2 were positive for PCV-2.

Three piglets had focal abscess formations in the lung with clusters of gram-positive bacteria consistent with the isolation of *Arcanobacterium pyogenes*. Two cases with focal lung necrosis with pleura involvement in the caudal lobes were consistent with pleuropneumonia in which *Actinobacillus pleuropneumoniae* was isolated.

Others results

The piglet with brachygnatia inferior, scoliosis and kyphosis had systemic nonsuppurative vasculitis and perivasculitis, myocarditis, encephalitis and meningitis (Tab. 1). The animal was immunohistochemically positive for PCV-2 and for encephalomyocarditis virus (EMCV) (Immunohistochemistry for EMCV, kindly

Table 2: Histological and bacteriological findings in the gut of 69 investigated piglets

Histological findings	n (= 69)	Bacteriological findings							
		<i>Campylobacter spp.</i>	<i>E. coli with F4 fimbria</i>	<i>E. coli O141</i>	<i>E. coli O139</i>	<i>Lawsonia intracellularis</i>	<i>Brachyspira spp.</i>	<i>Y. enterocolitica</i>	<i>Salmonella spp.</i>
Ileitis (necrotizing)	10	10	2	1	0	9	4	0	0
Jejunitis	13	10	3	2	0	0	4	0	0
Enterocolitis	11	9	1	0	2	0	1	0	0
Colitis	16	14	0	0	1	0	5	2	0
none	19	14	2	1	0	0	2	0	0

E.: *Escherichia*; Y.: *Yersinia*; spp.: species

performed at the Laboratory of Pathology, Aristotle University, Thessaloniki, Greece). The bacteriological examination of liver, kidneys and spleen revealed no specific bacterial pathogens. *Staphylococcus hyicus* and *A. pyogenes* respectively, were isolated in 2 of the 7 cases of arthritis or polyarthritis.

Serological findings

Of 57 piglets from 21 farms examined for the presence of serum antibodies against PCV-2, 38 piglets from 18 farms had a seropositive reaction, as measured by IPMA. Titres in these seropositive animals ranged from 1:50 to 1:100'000. The other 19 piglets were regarded as seronegative, having no reaction at the 1:50 starting dilution employed in this assay. In 2 of these 19 piglets with no detectable PCV-2 antibodies, PCV-2 antigen could be detected in the lymphatic organs, but the histological lesions were not consistent with PMWS. The 4 piglets with PMWS had titers of 1:800, 1:25 000, 1:50 000 and 1:100 000.

Discussion

In view of the worldwide prevalence of PCV-2, post-weaning multisystemic wasting syndrome does not seem to contribute significantly to post-weaning wasting observed in Switzerland. In contrast to the low number of PMWS cases or the immunohistochemical detection of PCV-2 antigen, antibodies against PCV-2 were frequent in the piglets examined. By immunohistochemical examination, only 11 out of 72 piglets (15%) showed detectable PCV-2 antigen in the lymphatic organs. Only 4 pigs (6%) of the 11 PCV-2 positive pigs had the additional histopathological lesions characteristic for PMWS according to Sorden (2000). These 4 pigs originated from 3 different farms.

The histological lesions in the 4 pigs with PMWS, namely depletion of the lymphatic organs with infiltration of histiocytes and giant cell formation, were as described in the literature (Allan and Ellis, 2000; Rosell et al., 1999). The macroscopic findings, however, were only present in a weakened degree. Three of the 4 piglets with PMWS showed enlarged lymph nodes, but this enlargement never exceeded a doubling of the usual size and was unremarkable at clinical examination. No animal showed an enlargement of the size described by Rosell (1999). Interstitial pneumonia was observed in only 1 of the animals with PMWS. The same pattern of interstitial pneumonia was found in 3 other animals with no detectable PCV-2 antigen. The non-collapse of the lungs described by Sorden (2000) and Allan (2000) was not present in any of the examined animals.

Two of the 4 PMWS piglets originated from the same farm. The piglets weaned on this farm not only suf-

fered from wasting but also had problems with respiratory distress, coughing and diarrhoea. Another piglet with atypical circovirus infection also originated from this farm. On the second farm with a PMWS-positive pig, the piglets showed diarrhoea of unknown cause with consecutive wasting. On the third farm with a PMWS-positive piglet, wasting was a result of strictures of the oesophageal opening into the stomach.

The other 7 piglets with detectable PCV-2 antigen in the lymphatic organs, were regarded as not suffering from PMWS according to Sorden (2000) since none of the histological changes characteristic of PMWS were detected. These atypically diseased animals suffered from other conditions such as PPE, mild chronic enteritis of unknown origin and Bordetella pneumonia. Other macroscopic visible causes for wasting could be found in 18 piglets and consisted for example of PPE, polyserositis, polyarthritis, osteomyelitis and gastric ulcers up to cardiac strictures. Among them, PPE could be found most frequently, namely in 9 piglets including 2 PCV-2 positive piglets. PPE was observed in Switzerland over the last few years in weaned piglets. But so far no study was carried out to determine its prevalence.

Other piglets with diarrhoea showed very often a mild to moderate chronic enteritis in the form of lymphoplasmacellular infiltrates in the lamina propria of small and/or large intestine. The detected bacterial pathogens in these piglets comprised *Campylobacter spp.*, enterotoxigenic or Shiga-Toxin-producing *E. coli*, *Brachyspira spp.* and *Yersinia enterocolitica*, but do not permit any distinct interpretation in conjunction with the gut lesions. However diarrhoea and mild enteritis were much more frequent than the detection of PCV-2 antigen.

The wide range of serum titers found in the 57 examined piglets were consistent with seroconversion at the time of weaning (Hampson and Trott, 1999; Rodriguez-Arrijoja et al., 2002). The serotiters do not allow any distinct interpretation because of the low number of investigated piglets per farm, the different ages and the unknown onset of the infection on each farm. Nevertheless, the detection of PCV-2 antibodies in 38 piglets from 18 farms suggests a high prevalence of the virus in the Swiss pig population.

Although the serological prevalence of PCV-2 can be assumed to be high in Switzerland, PMWS appears to occur quite rarely and hence PMWS does not seem to play a major role in wasting problem of pigs in Switzerland. In addition, the clinical and pathological changes such as the enlargement of the lymph nodes and non-collapsed lungs seem to occur in Switzerland either in a weakened form or not at all. Causes for this apparently different behaviour of PMWS under Swiss housing and management conditions are unknown and a good object for further follow up investigations.

Acknowledgements

The authors thank the technical staff of the Institute of Veterinary Pathology under the direction of Roseline Weilenmann for their histological and immunohistochemical expertise, Heidi Gerber of the IVI, Mittelhausern for preparing the monoclonal antibody. Dr.

N. Papaioannou from the Laboratory of Pathology, Aristotle University, Greece is thanked for the EMCV-diagnostic. The authors also thank the field veterinarians and the Swiss Swine Health Organization for the collaboration. This work was founded by the Swiss Federal Veterinary Office (Project number: 1.02.04).

Le Circovirus porcin comme cause possible de dépérissement des porcelets après le sevrage en Suisse

Le dépérissement après le sevrage dans les élevages de porcs représente un problème répandu dans le monde entier. Le «Postweaning multisystemic wasting syndrome» (PMWS) est un nouveau concept de maladie qui comprend les cas de dépérissement après le sevrage dans lesquels les animaux souffrent d'une infection due au Circovirus porcin de type 2 (PCV-2). Mis à part le dépérissement, on constate également des symptômes respiratoires, de la diarrhée, de la pâleur et parfois un ictère. Le but de ce travail était d'étudier l'importance en Suisse du PMWS et des autres maladies pouvant provoquer un dépérissement. On a examiné 72 porcelets sevrés et présentant un dépérissement, issus de 26 exploitations, quant à la présence de PCV-2 au moyen de l'immuno-histochimie et de l'histologie. En outre 57 porcelets issus de 21 exploitations ont été testés sérologiquement quant à la présence d'anticorps contre le PCV-2. Après son euthanasie, chaque animal a été examiné de façon détaillée, tant macroscopiquement qu'histologiquement et le tractus digestif ainsi que les organes parenchymateux ont été examinés du point de vue bactériologique. Le PCV-2 a pu être mis en évidence par immunohistochimie dans les organes lymphatiques de 11 des 72 porcelets. Toutefois, seuls 4 de ces 11 animaux présentaient des lésions histologiques typiques pour le PMWS. Des anticorps dirigés contre le PCV-2 ont par contre été décelés chez 70% des porcelets. Chez les porcelets qui ne présentaient pas d'infection à Circovirus on a pu trouver, entre autre, l'entéropathie proliférative porcine, des ulcères gastriques, des polysérosites et des polyarthrites. Les lésions histologiques rencontrées le plus fréquemment chez les porcs indemnes de PMWS se situaient dans le système digestif sous forme d'entérite chronique. Les résultats des examens sérologiques permettent de conclure à une large répartition de PCV-2 dans la population porcine suisse, par contre les maladies causées par ce virus n'ont pu être que rarement mises en évidence chez les animaux observés.

Circovirus porcino come possibile causa del deperimento dopo lo svezzamento dei suinetti in Svizzera

Nella produzione porcina l'apparizione di deperimento dopo lo svezzamento è un problema riconosciuto mondialmente. La «Postweaning multisystemic wasting syndrome» (PMWS) è un nuovo termine medico che include ogni caso di deperimento dopo lo svezzamento, in animali ammalati in cui è dimostrata un'infezione di Circovirus porcino tipo 2 (PCV-2). In concomitanza al deperimento intervengono clinicamente anche sintomi respiratori, diarrea, pallore e raramente itterizia. Lo scopo della presente ricerca di analizzare in Svizzera l'importanza della PMWS e di altre malattie che intervengono con il deperimento. Per individuare la presenza di PCV-2 sono stati esaminati tramite metodi immunohistochemici ed istologici 72 suinetti deperiti dopo lo svezzamento e provenienti da 26 allevamenti diversi. 57 suinetti da 21 allevamenti sono stati inoltre esaminati sierologicamente per quanto riguarda gli anticorpi contro il PCV-2. Ogni animale è stato esaminato dopo l'eutanasia accuratamente in modo macroscopico e istologico e il tratto gastrointestinale e gli organi parenchimatosi sono stati anche esaminati batteriologicamente. Negli organi linfatici di 11 su 72 suinetti è stato confermato immunostochimicamente il PCV-2. Di questi 11 animali solo 4 dimostravano dei cambiamenti istologici tipici della PMWS. Per contro nel 70% dei suinetti sono stati rintracciati degli anticorpi PCV-2. Nei suinetti deperiti non infettati dal circovirus le malattie alla base del deperimento comprendevano tra l'altro l'enteropatia proliferativa porcina, l'ulcera intestinale, la poliserosite e la poliartrite. Frequentemente l'esame istomorfologico ha riscontrato in casi senza PMWS mutamenti del tratto intestinale sotto forma di enteriti. I risultati dell'esame sierologico indicano una vasta propagazione del PCV-2 nella popolazione suina svizzera, per contro malattie dovute al PCV-2 sono raramente dimostrabili negli animali esaminati.

References

- Allan G.M., Ellis J.A.: Porcine circoviruses: a review. *J. Vet. Diagn. Invest.* 2000, 12: 3–14.
- Allan G.M., McNeilly F., Kennedy S., Daft B., Clarke E.G., Ellis J.A., Haines D.M., Meehan B.M., Adair B.M.: Isolation of porcine circovirus-like viruses from pigs with a wasting disease in the USA and Europe. *J. Vet. Diagn. Invest.* 1998, 10:3–10.
- Allan G., Mc Neilly F., Krakowka S., Ellis J.: PCV-2 infection in swine; more than just postweaning multisystemic wasting syndrome. *Vet. J.* 2003, 166:222–223.
- Arrington J.B.: Modified Warthin–Starry method (ph 4.0) for spirochetes and other microorganisms. In: *Laboratory methods in histotechnology*. Eds. E.D. Prophet, B. Mills, J.B. Arrington, L.H. Sobin, Armed Forces Institute of Pathology, American Registry of Pathology, Washington D.C., 1994, 214–215.
- Borel N., Bürgi E., Kiupel M., Stevenson G.W., Mittal S.K., Pospischil A., Sydler T.: [Three cases of postweaning multisystemic wasting syndrome (PMWS) due to porcine circovirus type 2 (PCV 2) in Switzerland]. *Schweiz. Arch. Tierheilk.* 2001, 143:249–255.
- Choi C., Chae C.: In-situ hybridization for the detection of porcine circovirus in pigs with postweaning multisystemic wasting syndrome. *J. Comp. Pathol.* 1999, 121:265–270.
- Clark E.: Pathology of post-weaning multisystemic wasting syndrome of pigs. *Proceedings of the Western Canadian Association of Swine Practitioners*, 1996, 22–25.
- Ellis J.A., Hassard L., Clark E., Harding J., Allan G.M., Willson P.I., Strokappe J.H., Martin K., McNeilly F., Meehan B.M., Todd D., Haines D.: Isolation of circovirus from lesions of pigs with postweaning multisystemic wasting syndrome. *Can. Vet. J.* 1998, 39:44–51.
- Hampson D.J., Trott D.J.: Spirochetal Diarrhea/Porcine Intestinal Spirochetosis. In: *Diseases of swine*. Eds. B.E. Straw, S. D'Allaire, W.L. Mengeling, D.J. Taylor, Blackwell science, Ames, 1999, 553–562.
- Harding J.C.: Post-weaning multisystemic wasting syndrome (PMWS): preliminary epidemiology and clinical presentation. *Proceedings of the Western Canadian Association of Swine Practitioners*, 1996, 21.
- Harding J.C.S., Clark E. G., Strokappe J.H., Willson P.I., Ellis J.A.: Post-weaning multisystemic wasting syndrome (PMWS): epidemiology and clinical presentation. *Swine Health and Prod.* 1998, 6:249–254.
- Harris D.L., Hampson D.J., Glock R.D.: Swine Dysentery. In: *Diseases of swine*. Eds. B.E. Straw, S. D'Allaire, W.L. Mengeling, D.J. Taylor, Blackwell science, Ames, 1999, 579–600.
- McNeilly F., McNair I., Mackie D.P., Meehan B.M., Kennedy S., Moffett D., Ellis J., Krakowka S., Allan G.M.: Production, characterisation and applications of monoclonal antibodies to porcine circovirus 2. *Arch. Virol.* 2001, 146:909–922.
- McOrist S., Gebhart C.J.: Porcine Proliferative Enteropathies. In: *Diseases of swine*. Eds. B.E. Straw, S. D'Allaire, W.L. Mengeling, D.J. Taylor, Blackwell science, Ames, 1999, 521–534.
- Rodriguez-Arrijo G.M., Segales J., Calsamiglia M., Resendes A.R., Balasch M., Plana-Duran J., Casal J., Domingo M.: Dynamics of porcine circovirus type 2 infection in a herd of pigs with postweaning multisystemic wasting syndrome. *Am. J. Vet. Res.* 2002, 63:354–357.
- Rosell C., Segales J., Plana-Duran J., Balasch M., Rodriguez-Arrijo G.M., Kennedy S., Allan G.M., McNeilly F., Latimer K.S., Domingo M.: Pathological, immunohistochemical, and in-situ hybridization studies of natural cases of postweaning multisystemic wasting syndrome (PMWS) in pigs. *J. Comp. Pathol.* 1999, 120:59–78.
- Sorden S.D.: Update on porcine circovirus and postweaning multisystemic wasting syndrome (PMWS). *Swine Health and Prod.* 2000, 8:133–136.
- Staebler S., Sydler T., Bürgi E., McCullough K., McNeilly F., Allan G., Pospischil A.: PMWS: an emerging disease identified in archived porcine tissues. *Vet. J.*, in press.
- Taylor D.J., Simmons J.R., Laird H.M.: Production of diarrhoea and dysentery in pigs by feeding pure cultures of a spirochaete differing from *Treponema hyodysenteriae*. *Vet. Rec.* 1980, 106:326–332.
- Thür B., Seuberlich T., Egli C., Hofmann M.A.: Differentiation of antibodies against European and North American type of PRRSV by indirect ELISA and indirect immunofluorescence. In: *Proceedings of the 4th Symposium on Emerging and Re-emerging Pig Diseases*, Rome, 2003, 85.

Corresponding author

Titus Sydler, Institute of Veterinary Pathology, University of Zurich, Winterthurerstrasse 268, CH-8057 Zurich, Switzerland; E-Mail: tsyd@vetpath.unizh.ch

Received for publication: 24 March 2004

Accepted in present form: 14 May 2004

Remarks on the current PMWS situation in Switzerland (2004)

T. Sydler¹, E. Buergi²

¹Institute of Veterinary Pathology, ²Department of Farm Animals, Section of Swine Medicine, University of Zurich.

Only few cases of PMWS were found in farms with increased wasting problems in the years 2001 and 2002 (Staebler et al., 2004). However the current situation seems to have changed. Since the beginning of 2003 we have observed a marked increase in PMWS cases submitted for routine necropsy. At least 6 farms were affected in 2003 and 21 additional farms by mid-2004. The PMWS positive weaner and fattening pigs originated from 11 finisher herds, from 12 breeding herds and from 4 specialized herds raising weaned piglets to 25 kg. The milder course of PMWS in the rare cases described by Staebler et al. (2004) seems to have altered. Nearly all piglets in the more recent cases showed severe lesions, at least at the histological level, and high virus antigen loads. Some of the animals had marked changes such as massive serous effusions in the body cavities, subcutaneous oedema in the eyelids, forehead, mesenterium, submucosa of the stomach and obvious interstitial and alveolar oedema of the lung. Pneumonia was observed commonly as multiple small

interstitial foci. Some animals had a markedly enlarged colon with fluid contents. There was never a severe enlargement of the peripheral lymph nodes, in some cases the mesenteric lymph nodes were obviously enlarged. Porcine Dermatitis Nephritis Syndrome (PDNS) with both the typical glomerulonephritis and skin lesions was noted only once. Four finishers from 2 farms had immune complex glomerulonephritis without skin lesions and 2 pigs from 1 farm had a severe interstitial nephritis that macroscopically was indistinguishable from chronic glomerulonephritis. The lesions contained viral antigen.

We conclude that Circovirus infections may have recently developed into a serious problem in Switzerland.

Staebler S., Buergi E., Litzemberger B., McCullough K., McNair I., McNeilly F., Pospischil A., Sydler T.: Porcine circovirus as a possible cause of postweaning wasting in pigs in Switzerland. Schweiz. Arch. Tierheilk. 2004, 146: 461–469.